

## CARDIOLOGY

# 5 signs your arteries may be clogged

Be aware of these symptoms.



Coronary artery disease is almost always due to the gradual build-up of cholesterol and other fatty materials (called atheroma or atherosclerotic plaque) on the wall of a coronary artery. This process is called atherosclerosis. As the atheroma grows, it may bulge into the artery, narrowing it and partially blocking the blood flow. If the blockage is significant, it causes myocardial ischaemia, which can result in angina pain. If the atheroma ruptures suddenly, it triggers the formation of a blood clot (thrombus), which can further narrow or completely block the artery. The consequences of this acute ischaemia are referred to as acute coronary syndrome. In a heart attack, the area of the heart muscle supplied by the blocked artery dies, a process called myocardial infarction.

The classic symptoms of coronary artery syndrome include a feeling of pressure in the chest, a squeezing or full sensation or actual chest pain. This may be accompanied by pain in one or both arms, jaw, back, stomach or neck. Other symptoms include shortness of breath, nausea, vomiting, light-headedness and sweating. Symptoms develop when the heart is working harder and goes away with rest. At the other end of this spectrum is acute myocardial infarction (heart attack), when the blood supply to the heart is completely cut off. In a heart attack, symptoms can be much worse and pain occurs even at rest. There may be associated breathlessness and sweating. Angina drugs do not help — this is a medical emergency.

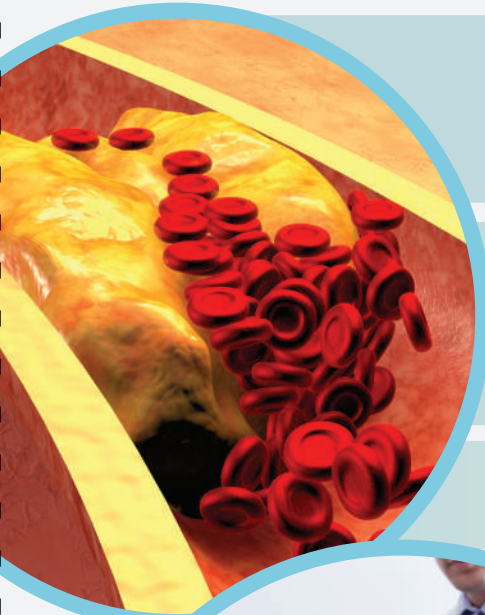
Some overlooked warning signs of clogged arteries include:

- 1 Atypical signs** Women are more likely than men to experience symptoms of acute coronary syndrome that do not occur in this typical fashion. Instead, they experience more of the other symptoms, such as light-headedness, nausea, extreme fatigue, fainting, dizziness or pressure in the upper back with or without chest pain.
- 2 Silent ischaemia** This is of particular concern for diabetics. They are more likely to be without chest pain in the setting of unstable angina or a myocardial infarction and thus late presentation contributes to a higher mortality (risk of dying) in these patients in terms of late diagnosis and presentation. It is believed that diabetes-related nerve damage blunts the heart pain and hence symptoms are not noticed.



**Dr Eric Hong**  
Cardiologist

**EH Heart Specialist Pte Ltd**  
3 Mount Elizabeth  
#03-09 Mount Elizabeth Medical Centre  
Singapore 228510  
Tel: 6736 1068  
www.eheartspecialist.com




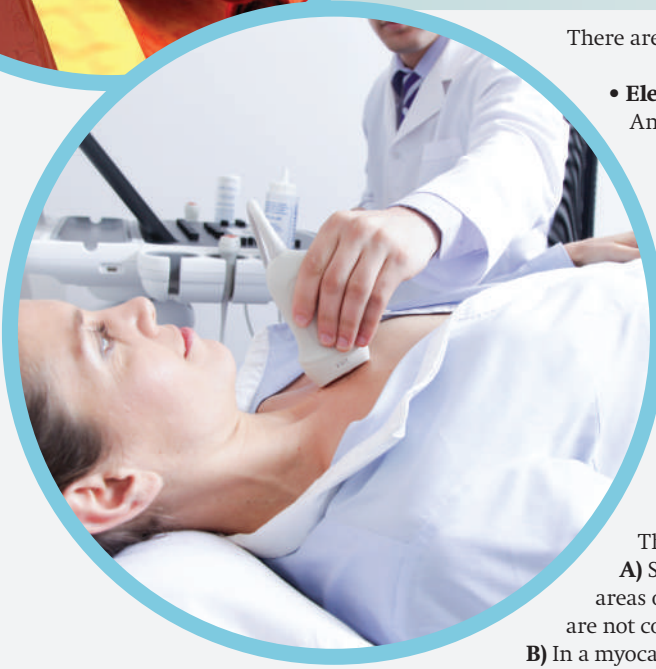**3 Erectile dysfunction** This is an inability to get and keep an erection firm enough for sex. This could be an early-warning sign of current or future heart problems. In the past, it was believed that plaque build-up reduces the blood flow in the penis, making erections difficult. It is now believed that this occurs due to the dysfunction of the inner lining of the blood vessels and smooth muscle, leading to a reduction of blood supply to the heart and the penis.

**4 Peripheral artery disease** There is a narrowing of the peripheral arteries to the legs, stomach, arms and head — most commonly in the arteries of the legs. This is again due to atherosclerosis. The most common symptom is cramping, pain or tiredness in the leg or hip muscles while walking or climbing stairs, which goes away with rest but returns when one walks again. If left untreated, it can result in ulcers and gangrene. Such patients frequently have concomitant coronary artery disease, heart attack and stroke.

**5 A diagonal ear lobe crease** Studies have indicated that this could signal the presence of cardiovascular disease. The symptom is also called Frank's sign.

There are various tests to determine if your arteries are clogged. These include:

- **Electrocardiogram (ECG)** This records electrical signals as they travel through the heart. An ECG can often reveal evidence of a previous heart attack or one that's in progress.
- **Echocardiogram** This produces images of the heart, which will indicate whether all parts of the heart wall are contributing normally to your heart's pumping activity. Parts that move weakly may have been damaged during a heart attack or are receiving too little oxygen.
- **Standard Exercise Stress Test** This can be done by walking or running on a treadmill or pedalling on a stationary bike, and provides information on how the heart works during physical stress. Abnormal changes in the heart's rhythm or electrical activity, abnormal blood pressure readings, and symptoms such as shortness of breath or chest pain may be indicative of possible coronary artery disease.
- **Imaging Stress Test** Pictures are taken of the heart during exercise and at rest, which show how well blood is flowing in the heart as well as the pumping action of the heart. These tests tend to detect coronary artery disease better than the standard exercise stress test.
  - A)** Stress echocardiography uses sound waves to create a moving picture of the heart and shows areas of poor blood flow to the heart, dead heart muscle tissue, and areas of the heart muscle that are not contracting well.
  - B)** In a myocardial perfusion scan, a small amount of radioactive substance (often called a tracer, isotope or radionuclide) such as technetium is injected into the blood so that the blood flow can be detected by a special camera. The scan is done in two parts — stress and rest — to see the effects of physical stress on the blood flow. For the stress component, a medicine is given to increase the heart rate.
  - C)** Cardiac PET (positron-emission tomography) is also a nuclear medicine functional imaging technique, and detects blood flow at rest and at stress. The system detects pairs of gamma rays emitted indirectly by a positron-emitting radionuclide tracer. Three-dimensional images of tracer concentration within the body are then accomplished with the aid of a CT X-ray scan performed on the patient during the same session in the same machine.
- **Multi-slice Coronary Computed Tomography (CT) Angiogram with Calcium Scoring** This is a noninvasive diagnostic tool that produces multiple images of the heart. These images can be reformatted in multiple planes and can even generate three-dimensional images. Hence, information about the presence, location and extent of calcified plaques in the coronary arteries can be obtained. It can be combined with a calcium-score screening to detect the calcium deposits in atherosclerotic plaque and used to evaluate the risk of future artery disease.
- **Coronary Angiogram** This is to view the blood flow in the coronary blood vessels. This is done by injecting a dye through a long, thin, flexible tube that is threaded through an artery usually in the leg or hand to the arteries in the heart. The dye outlines narrow spots and blockages on the X-ray images. 



“ In a heart attack, the area of the heart muscle supplied by the blocked artery dies, a process called myocardial infarction. ”